

**PATIENT**

Vera Hulsey

**SPECIES**

Canine

**BREED**

Mixed

**SEX**

Female Spayed

**AGE**

11.3.15

**WEIGHT**

14.4lbs

**PRESENTING CLINICAL SIGNS**

History: Recheck echo. Intermittent cough when she lies down. Otherwise, no concerns.

-Radiographs (3/21/22): Showed normal lung fields, mild cardiomegaly, pectus excavatum.

-Current medications: Furosemide 20mg ¼ q48hrs since Nov 2020, Meloxicam 0.5mg/mL- dose for 8-9lb dog SID since Nov 2020, Optimune from rescue when adopted.

-Sedation used: Not required to complete full diagnostic ultrasound.

-Pertinent previous ultrasound results (11/2020 MML): Mild to moderate MR, mild LAE, no LVE, mild TR, mild PAH. TR: 3.1, LA: 1.8, LV: 2.8.

-STAT: Not requested

-Imaging performed by: Andi Parkinson, RDMS.

**ECHOCARDIOGRAM FINDINGS** \*Chest conformation limits image quality.

2D, m-mode, color flow and doppler imaging is available. Mild thickening of mitral valve leaflets with no prolapse into the left atrial lumen. Mild to moderate eccentric mitral regurgitation with mild left atrial dilation. Normal MR velocity. Normal LV diameter with adequate myocardial function. The tricuspid valve appears mildly thickened with mild tricuspid regurgitation. Velocity consistent with normal pulmonary pressures. Normal right atrial and ventricular diameter and morphology indicating no overt evidence of pulmonary arterial hypertension. The pulmonic and aortic valves are normal in morphology and mobility. Normal pulmonic and aortic outflow velocities with laminar flow. No obvious aortic or pulmonic insufficiency. No pericardial or pleural effusion noted. No obvious cardiac masses.

**CARDIAC CHART****INTERPRETED BY**Maggie Machen Lamy,  
DVM, DACVIM  
(Cardiology)**HOSPITAL NAME**

Warm &amp; Fuzzy Vet

**REFERRING VET**

Dr. Hepner

**INVOICE**

23573

**DATE**

4.11.22

CANINE CARDIAC PARAMETERS	MR VMAX (m/s)	TR VMAX (m/s)	LA/AO (Boon method)	LA/AO (Heart Base; Swe)	FS (%)	EF (%)	EPSS (cm)
NORMAL PARAMETER	4.5-5.5	<2.7	1.3	<1.6	28-40	40-100	<0.6
PATIENT	5.6	2.6	NM	1.3	42	75	NM
CANINE CARDIAC PARAMETERS	HR (BPM)	AV VMAX (m/s)	PV MAX (m/s)	BODY WEIGHT (kg)	LA 2D short axis Base view (cm)	LVIDd Avg; 2D and m-mode short axis (cm)	LVIDs Avg; 2D and m-mode short axis (cm)
NORMAL PARAMETER	50-100	0.7-1.7	0.7-1.6	BELOW	BELOW	BELOW	BELOW
PATIENT	NM	1.0	1.2	6.5	1.34	2.4	1.4
*Normal chamber parameters expressed as a mean value (SD)				3	1.27 (5.3)	2.46 (2.46)	1.36 (5.5)
<b>BODY WEIGHT DEPENDENT PARAMETERS</b>				5	1.40 (4.5)	2.74 (5.2)	1.60 (4.7)
*Note: All measurements based upon multi-modal images and methods. An average value is reported.				10	1.50 (3.8)	3.27 (3.5)	2.06 (3.1)
				15	1.83 (2.0)	3.71 (2.4)	2.43 (2.1)
				20	2.02 (1.9)	4.14 (2.2)	2.80 (2.0)
				25	2.18 (2.4)	4.48 (2.9)	3.10 (2.5)
				30	2.33 (3.3)	4.83 (3.9)	3.39 (3.4)
				35	2.48 (4.3)	5.17 (5.0)	3.69 (4.5)
				40	2.62 (5.2)	5.48 (6.1)	3.96 (5.4)
				50	2.88 (7.1)	6.07 (8.3)	4.46 (7.4)

Adapted from June Boon, Veterinary Echocardiography, 1998  
 Rishniw M and Hollis NE, J Vet Intern Med 2000; 14:429-435  
 Hansson et al, Vet Rad and Ultrasound 2002  
 Bonagura et al. Echocardiography: principles of interpretation, Vet Clin North Am 15:1177, 1995

## INTERPRETATION OF THE FINDINGS & FURTHER RECOMMENDATIONS

Chronic degenerative valve disease causing mild to moderate mitral and mild tricuspid regurgitation persists. Compared to the prior study, there is no significant progression with stable to mildly improved left heart dimensions. Pulmonary pressures measure normal; however, this is considered overall stable.

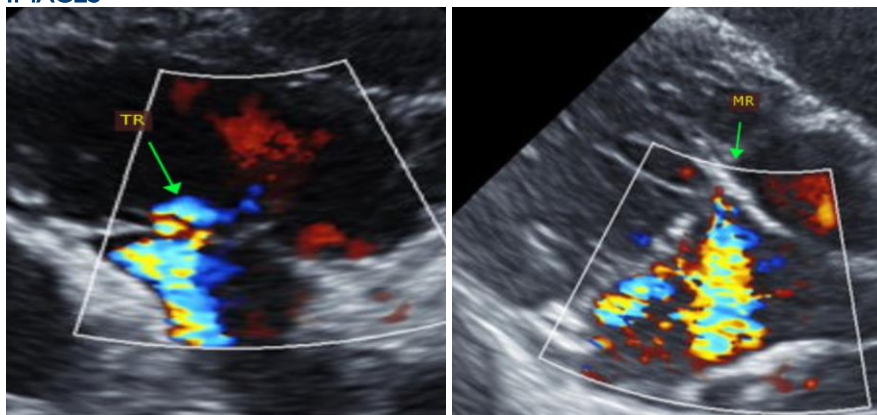
Given these findings no cardiac medications remain indicated. As was discussed in the previous report, Lasix is likely unnecessary. Continued assessment of progression in the future will help predict long term prognosis, which is highly variable at this stage (B1). Omega fatty acid supplementation and mild salt restriction may be of some long-term benefit. Monitor for development of a cough, labored breathing, exercise intolerance or collapse episodes.

Given these findings, the cough is unlikely to be cardiac in origin and primary respiratory causes should be considered. Consider further respiratory work up/treatment (hydrocodone, taper course of steroids, Enrofloxacin, TTW/BAL, etc.).

Anesthetic risk is considered mild if needed. Cardiac protective drug choices (opioid/benzodiazepine premedication, propofol or alfaxalone induction, isoflurane gas) are recommended. Pre-oxygenate for 5-10 minutes prior to induction. Monitor for arrhythmias, hypotension, and hypoxia both intra and post-operatively and intervene as necessary. Mild IV fluid restriction is recommended to avoid fluid overload. Avoid heart rate stimulating drugs such as atropine unless clinically indicated.

Recommend conservative monitoring with a recheck echocardiogram in 6-12 months, sooner if any development of clinical signs.

## IMAGES



**The information and recommendations provided are based on the images presented by the referring veterinarian. No evaluation can be communicated regarding pathology that was not visible in the image/video clips provided.**

Thank you for this referral. This report was generated using transcription software, and minor dictation errors may be present. If the clinical or image interpretation does not parallel your findings or if I can be of any further assistance, please contact me.

**Maggie Machen Lamy, DVM**  
**Diplomate of the American College of Veterinary Internal Medicine (Cardiology)**  
**info@sonopath.com**